

# Pregnancy Outcome of Abnormal Nuchal Translucency: A Systematic Review

NASIBEH ROOZBEH<sup>1</sup>, MARYAM AZIZI<sup>2</sup>, LEILI DARVISH<sup>3</sup>

## ABSTRACT

**Introduction:** Nuchal Translucency (NT) is the sonographic form of subcutaneous gathering of liquid behind the foetal neck in the first trimester of pregnancy. There is association of increased NT with chromosomal and non-chromosomal abnormalities.

**Aim:** The purpose of this systemic review was to review the pregnancy outcome of abnormal nuchal translucency.

**Materials and Methods:** The present systematic review was conducted by searching English language articles from sources such as International Medical Sciences, Medline, Web of science, Scopus, Google Scholar, PubMed, Index Copernicus, DOAJ, EBSCO-CINAHL. Persian articles were searched from Iranmedex and SID sources. Related key words were "outcome", "pregnancy", "abnormal", and "Nuchal Translucency" (NT). All, randomized, descriptive, analytic-descriptive, case control study conducted during 1997-2015 were included.

**Results:** Including duplicate articles, 95 related articles were

found. After reviewing article titles, 30 unrelated article and abstracts were removed, and 65 articles were evaluated of which 30 articles were duplicate. Finally 22 articles were selected for final analysis. Exclusion criteria were, case studies and reports and quasi experimental designs. This evaluation has optioned negative relationship between nuchal translucency and pregnancy result. Rate of cardiac, chromosomal and other defects are correlated with increased NT $\geq$ 2.5mm. Cardiac disease which were associated to the increased NT are heart murmur, systolic organic murmur, Atrial Septal Defect (ASD), Ventricular Septal Defect (VSD), tricuspid valve insufficiency and pulmonary valve insufficiency, Inferior Vena Cava (IVC) and Patent Ductus Arteriosus (PDA). The most common problems that related with increased NT were allergic symptoms.

**Conclusion:** According to this systematic review, increased NT is associated with various foetal defects. To verify the presence of malformations, birth defect consultations with a perinatologist and additional tests are required.

**Keywords:** Chromosomal abnormalities, Defect, Foetal

## INTRODUCTION

Ultrasonography is regularly used for prenatal care because it allows examination of foetal health in the early stages of pregnancy [1,2]. Nuchal Translucency (NT) is the sonographic appearance of subcutaneous accumulation of liquid in the back of the foetal neck in the first trimester of pregnancy (11-14 gestational weeks of pregnancy). NT measurement is an excellent and sensitive screening test for foetal chromosomal abnormalities. The aetiology for the phenomenon includes cardiac failure secondary to structural malformation, disorders in the extracellular matrix, and unusual or delayed development of the lymphatic system. NT is detected in about 5% of the foetuses during screening. NT size above the 95<sup>th</sup> centile is said to be an increased NT, the thickness of which is based on Crown Rump Length (CRL). CRL is undetected in 5% of the screened foetuses, increasing NT thickness is based on the CRL [1,2]. At minimum CRL (45 mm) and maximum CRL (84 mm) in gestational age 11 to 13 + 6 weeks, NT is between the 50<sup>th</sup> percentile and 95<sup>th</sup> percentile. There is an association between increased NT and chromosomal and non-chromosomal abnormalities [2-7]. Prevalence of abortion, foetal death and foetal anomalies increase exponentially with NT thickness [8]. Increasing NT is associated with the risk of a broad spectrum of congenital anomalies, varying from isolated structural deficiencies to genetic diseases and neurodevelopmental delay, which often become manifest in the first years of life [4-6]. Increasing NT is a reason to identify the number of developmental delay. Many of syndromes associated with an increased NT (such as chromosomal abnormality) can cause developmental defect in neonates [8]. Thus, determining the outcomes of foetuses with increased NT is

necessary. As primary searches in the available databases show no systematic studies evaluating the pregnancy outcomes of abnormal NT, the main purpose of this study was to explore the outcomes of this abnormality.

## MATERIALS AND METHODS

### Literature Search Criteria

English-language databases, including International Medical Sciences, Medline, Web of Science, Scopus, Google Scholar, PubMed, Index Copernicus, DOAJ, EBSCO-CINAHL, as well as Persian-language databases, including Magiran, were searched using keywords such as "NT," "abnormal," "outcome," "pregnancy," "increased," "foetal," and "Nuchal translucency." The searches were performed using the Boolean operators OR and AND between main phrases and the keywords were obtained from particular matters of the topic under study. Furthermore, relevant keywords and Boolean operators were selected to modify the search strategy in each database. No language preference was specified during the database searches or applied during evaluation of the obtained studies' reference lists.

### Inclusion and Exclusion Criteria

This paper included all published articles from 1997 to 2016. All randomized, descriptive, analytic-descriptive and case control study conducted during 1997 to 2015 was included. Exclusion criteria were, case studies and reports and quasi experimental designs.

### Data Collection

Independent searches were performed by two researchers from

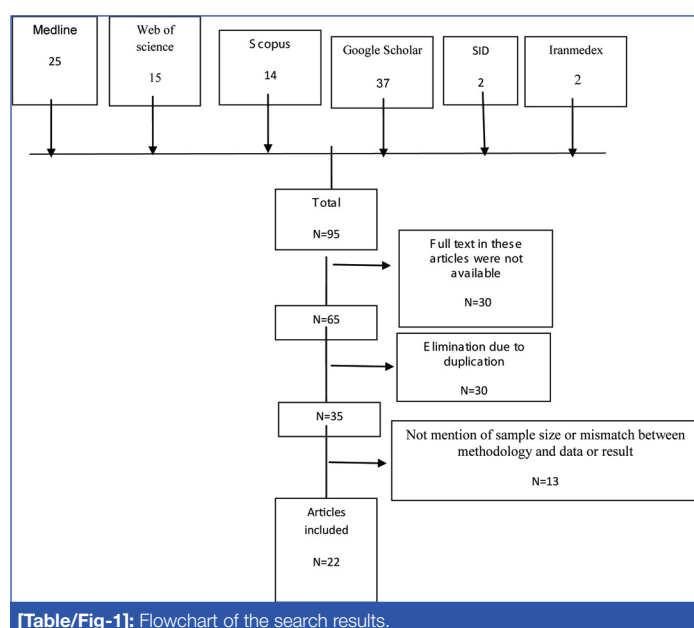
April 2016 to May 2016. If disagreement between authors was encountered, a third researcher was consulted to resolve this disagreement. The Strengthening the reporting of observational studies in epidemiology (STROBE) check list was used [9] to evaluate standard reporting quality in the obtained articles and studies with a quality assessment below 60% were excluded from this work.

### Assessment of Study Quality

The Cochrane Risk of Bias Tool [10] was used for bias assessment.

## RESULTS

Including duplicate articles, 95 related articles were found. After reviewing article titles, 30 unrelated article and abstracts were removed and 65 articles were evaluated of which 30 articles were duplicate. Finally, 35 articles were analysed. Thirteen articles had no mention of sample size or there was mismatch between methodologies, data or results, finally twenty two articles were selected for final analysis [Table/Fig-1]. Results of study review are summarized in [Table/Fig-2] [11-32].



## DISCUSSION

Results have demonstrated that there is relationship between an increase foetal NT in pregnancy and adverse outcomes. An NT of above 2.5 mm was commonly found among different studies. Analysis of the articles revealed that major cardiac problems were more highly associated with increased NT in fetuses than other abnormalities. Cardiac defects related to the increased NT included heart murmur, systolic organic murmur, ASD, VSD, murmur, tricuspid valve insufficiency and pulmonary valve insufficiency, Intraventricular Communication (IVC) and Patent Ductus Arteriosus (PDA) [11-14]. Allergic symptoms were also common in increased NT such as allergies to antibiotics, food, pollen or animals [13]. Examination of the relationship between increased NT and chromosomal defects revealed that the incidence of chromosomal defects increases with foetal NT thickness. Increased NT was correlated with trisomy 21, trisomy 18, triploidy, monosomy X and trisomy 13. There was a stable and major increase in the mean foetal heart rate in trisomy 21 pregnancies [15-19]. Studies confirmed the association between Klinefelter syndrome and increased NT [20,21]. NTs of 4 mm to 22 mm have been correlated with aneuploidy, Turner's syndrome, cystic hygroma, hydrops foetalis, and aneuploidy [22]. In 2013, Bijok J et al., found that Intra Uterine Foetal Death (IUFD), structural abnormalities, neonatal death, genetic disorders, and other major anomalies were among the adverse pregnancy results of increased NT [23]. The association between increased NT and a wide range of structural abnormalities and genetic syndromes suggests the increased need for follow-up scans, including foetal echocardiography and genetic testing [24-27]. Researchers believe that actual associations among one or more of several mechanisms, including venous congestion in the head and neck in relation to the contraction of the foetus in amniotic rupture sequence, cardiac dysfunction related to disorders of the heart and great vessels, lymphatic drainage failure due to abnormal development of the lymphatic system and neuromuscular disorders, may exist; vitamin B9 deficiency, anaemia and hypoproteinemia have also been associated with increased NT and should be evaluated in this case [28,29]. A broad series of disorders have been reported in fetuses with increased NT [30-32]. Other defects in increased NT were strawberry capillary naevi, haemangiomas, umbilical hernias, inguinal hernias, hypospadias, testis, mild undescended hydrocele, positional talipes equinovarus, clinodactyly, finger [33].

Authors	Type of study	Method	Result	STROBE score
GHI T et al., [11] 2001	Cross-sectional	Echocardiography was performed in 1319 chromosomally normal fetuses with increased NT. The incidence of major cardiac defects was examined.	Major cardiac defects were in 4.5% of fetuses with a nuchal translucency thickness in the range of 2.5–3.4 mm.	18
Zosmer N et al., [12] 1999	Cross-sectional	Echocardiography was performed in 398 chromosomally normal fetuses with NT above the 2 mm, scan was carried out at 17-22 weeks and 20-22 weeks. Pregnancy outcome was obtained in all of the cases.	Major cardiac defects were present in 29 cases. Echocardiography was carried out at 13-17 weeks and an abnormality was suspected in 24 of the cases.	18
Hiippala A et al., [13] 2001	Cohort	Clinical examination and detailed cardiac evaluation were carried out in 50 chromosomally normal children at the age of 2.4–7.1 years who had a nuchal translucency measurement of $\geq 3$ mm at 13–15 weeks' gestation.	Major cardiac defects were identified in 8% of the children. The growth of all children was within normal limits. One child had Noonan syndrome, one had a cleidocranial dysplasia and a third had a developmental delay together with an unrecognized syndrome. Webs in the neck region were noticed in two children, with no associated pathology.	17
Vieira LA et al., [14] 2013	Cross-sectional	Foetuses with an NT above P95 and a normal karyotype were analyzed. Postnatal echocardiography (ECHO), weight, length and Apgar score at birth, and neuropsychomotor development by the ages and stages questionnaire evaluated.	Abortion, foetal death, several structural abnormalities and IVC was shown, postnatal echocardiography revealed the persistence of IVC in one case and one case of Atrial Septal Defect (ASD) and Patent Ductus Arteriosus (PDA). Of the 40 surviving children, only one showed delayed speech development and another presented autism.	18
Matias A et al., [15] 1998	Cross-sectional	Ductus venosus flow velocity waveforms were obtained immediately before foetal karyotyping in 486 consecutive singleton pregnancies at 10–14 weeks of gestation. All cases were screened for chromosomal defects by a combination of maternal age and foetal nuchal translucency thickness.	There were 63 chromosomal defects trisomy 18, seven cases of trisomy 13, three cases of Turner's syndrome and three cases of triploidy. In 57 cases there was reverse or absent flow during atrial contraction. Abnormal ductus venosus flow was also observed in 13 (3.1%) of the 423 chromosomally normal fetuses.	16

Authors	Type of study	Method	Result	STROBE score
Jauniaux E et al., [16] 1996	Cross-sectional	Foetal heart rate, umbilical artery pulsatility index, end diastolic flow, nuchal translucency thickness and placental thickness were recorded in 250 women with a viable singleton pregnancy undergoing chorionic villous sampling for foetal karyotyping at 11-14 weeks of gestation	The foetal karyotype was normal in 210 cases and abnormal in 40, including 21 with trisomy 21, 13 with trisomy 18, three with triploidy, two with monosomy X and one with trisomy 13.	17
Maymon R et al., [17] 2000	cohort	Long-term pregnancy outcome and infancy prognosis of 78 fetuses with NT > 95 <sup>th</sup> centile of the normal range for Crown-Rump Length (CRL) assess.	In 40% of the cases increased NT related to chromosomal abnormality. The chance of a normal outcome dropped to 50% in four cases with maternal age ≥30 years and NT ≥5 mm.	17
Schwarzler et al., [18] 1999	Prospective.	Measurements of crown-rump length and NT. Pregnancy outcome was obtained through karyotyping, outcome questionnaires and examination of the newborn infants.	Screening was positive in 5.1% fetuses. Foetal karyotype was abnormal in 23 cases, including twelve with trisomy 21, five trisomy 18, one trisomy 13, one trisomy 10, one monosomy X and two triploidies. Only one out of nine major congenital heart defects in this population was found.	16
Westin M et al., [19] 2006	Cross-sectional study	An NT measurement was made in 16, 383 consecutive euploid fetuses derived from an unselected pregnant population.	A total of 127 cases with a diagnosis of heart defect confirmed by cardiac investigations after birth or at autopsy. Of these, 55 defects were defined as major, of which 52 were isolated, corresponding to a prevalence of major heart defects in chromosomally. NT >or= 95 <sup>th</sup> centile with regard to an isolated major heart defect.	21
Zoppi MA et al., [20] 2001	Cohort	Foetal NT thickness and crown rump length were measured at 10–14 weeks of gestation in 12, 495 pregnancies.	There were 64 fetuses with trisomy 21 and 46 with other chromosomal defects. In 184 multiple pregnancies, there were four fetuses with chromosomal abnormalities.	19
Nicolides KH et al., [21] 2005	Cross-sectional study	First-trimester combined screening for trisomy 21 was carried out in 75, 821 singleton pregnancies with live fetuses at 11+0 to 13+6 gestational weeks.	Chromosomal abnormalities were identified in 544 pregnancies, including 325 cases of trisomy 21. Increased NT associated to trisomy, trisomy 18, 13 and other chromosomal defects.	21
Taipale P et al., [22] 1997	Cohort	Trans vaginal ultrasonography performed in 10,010 women less than 40 years of age with live singleton fetuses at 10 to 15.9 weeks of gestation. Increased foetal nuchal translucency was defined as an area of translucency at least 3 mm.	Abnormal karyotype was seen in abnormal NT in 76 fetuses.	18
Bijok J et al., [23] 2013	A retrospective study	Children development in 87 women with increased foetal nuchal translucency and normal karyotype that underwent chorionic villus sampling at our department. Mean observation period was 12 months after birth.	NT was significantly higher in newborns with adverse pregnancy outcome than in after a normal anomaly scan at 20 weeks gestation the risk of adverse outcome was 14.5%. The rate of neurodevelopmental delay was 3.4 % and was not higher than in the general population.	20
Ayrás O et al., [24] 2013	Cross-sectional	1063 singleton pregnancies with increased NT at the first screening ultrasound examination were included. Pregnancy outcomes and short-term outcomes of the newborns were recorded and analyzed.	Structural defects or genetic disorders were observed in 9% of cases, of which 58% resulted in live birth, 34% in termination of pregnancy, and 8% in miscarriage or perinatal death.	17
Dane B, et al., [25] 2008	Nested case-series	CRL, NT was recorded. A total of 1930 pregnant women were screened between 11-14 weeks. Follow up information was obtained by a review of medical records and self-reports from patients.	The prevalence of increased foetal NT was 1.4%. Among these, 12 showed increased foetal NT as an isolated finding. In the group with additional abnormalities were found to have chromosomal abnormalities. For all cases with increased foetal NT, total incidence of adverse outcome was 62%.	18
Lithner CU, et al., [26] 2015	Cohort	Foetal NT was measured in 55, 123 singleton pregnancies.	Of the 139 high NT pregnancies with normal karyotype, 110 resulted in live births, one IUFD, 23 TOP and five MC. Structural foetal defects were found in 28, of which seven resulted in live births and 21 were terminated. The most common structural defect was cardiac defects.	16
Brady AF et al., [27] 1998	Cross-sectional study	Clinical follow up of 89 chromosomally normal live births that in foetal life had a minimum NT thickness of 3.5 mm and a comparison group of 302 infants whose foetal nuchal translucency thickness at 10-14 weeks of gestation was less than 3.5 mm was performed.	Major abnormalities, mainly structural defects of the cardiovascular or skeletal systems. Delay in achievement of developmental milestones was observed in one of the infants with increased translucency and in one of the comparison group.	19
Souka AP et al., [28] 2001	Retrospective study	1320 chromosomally normal singleton pregnancies with nuchal translucency of ≥ 3.5 mm evaluated. In addition to foetal karyotyping these patients were managed with follow up scans at 14 to 16 and 20 to 22 Weeks.	In the 1,320 pregnancies there were 68 spontaneous abortions or intrauterine deaths, 18 neonatal and infant deaths and 154 terminations of pregnancy. In the 1,080 survivors, 60 had abnormalities requiring medical or surgical treatment or leading to mental handicap.	16
Tahmasebpur A et al., [29] 2012	Cross-sectional study	A total of 186 cases with NT ≥ 95 <sup>th</sup> centile who attended for the first trimester screening were studied. All cases with increased NT including those with normal karyotype were followed up with anomaly scan at 18-22 weeks and foetal echocardiography at 22 to 24 weeks. Pregnancy outcome was extracted from delivery records and paediatrics notes and telephone interviews.	Almost 19.8% were abnormal karyotype, including 29 cases of trisomy 21, three of trisomy 18, two of trisomy 13, three of Turner syndrome. 4.6% of cases were found to have malformation antenatally and 4% cases postnatally. 11.4% women elected termination of pregnancy without further follow up. There were 4.6% foetal loss and 1.3% hydrops foetalis.	17
Mula R et al., [30] 2012	Cohort	Singleton fetuses with NT above the 99(th) percentile and normal karyotype scanned. Work-up included first- and second-trimester anomaly scan, first- and second-trimester foetal echocardiography, and in selected cases infection screening and genetic testing.	There were seven spontaneous foetal losses, 38 terminations of pregnancy and two postnatal deaths. Among the 124 survivors, 12 were born with structural abnormalities. Neurodevelopmental follow up was completed in 108 of the 124 survivors and four showed moderate to severe impairment. Overall, a structural abnormality or genetic syndrome was diagnosed in 50 fetuses/newborns. Interestingly, a single umbilical artery was found in six fetuses with no structural defects at birth.	19

Authors	Type of study	Method	Result	STROBE score
Scholl J et al., [31] 2012	A retrospective cohort study	First-trimester fetuses with ultrasound-diagnosed nuchal cystic hygroma collected over a 10-year period.	A major congenital anomaly occurred in 28.8%. Perinatal loss occurred in 39% Overall, an abnormal outcome occurred in 86.6% of fetuses.	19
Muru K et al., [32] 2013	Cohort	Screening tests of 5,257 pregnant women were analyzed during one-year period.	Among the 74 pregnant women, a structural or genetic abnormality was diagnosed in 16 cases, foetal death occurred in 12 cases and child was healthy at the age of two years in 31 cases. Four children had with congenital anomalies and/or syndromes: two had congenital heart disease – atrial septal defect and ventricular septal defect with patent ductus arteriosus, one Silver-Russell syndrome and one congenital adrenal hyperplasia.	18

**[Table/Fig-2]:** Details of the studies used for analysis [11-32].

Echocardiography and foetal anomaly scan can detect many abnormalities from the 12<sup>th</sup> week of pregnancy. Chorionic villus sampling is used as follow-up scan at 14-16 weeks, evolution and diagnosis NT or delete of many birth defects. The true prevalence of developmental neuronal delay is likely to be underestimated because abnormalities may not appear until several years after birth in many cases. This study offers prenatal research that can help determine adverse pregnancy outcomes.

## LIMITATION

The weaknesses of this review include a lack of access to all related journals and a lack of case-control studies. Given the importance of determining whether a fetus presents congenital abnormalities during pregnancy, further studies in different countries are necessary for determination of NT cut-off. Systematic reviews for evaluating the neurodevelopmental outcome of fetuses with increased nuchal translucency are also recommended.

## CONCLUSION

Systematic reviews of pregnancy outcomes with increased NT provide useful information for physicians and health care practitioners and support decision-making and the selection of interventions to apply during pregnancy. Increased NT is associated with various foetal defects. To verify the presence of malformations, birth defect consultations with a perinatologist and additional tests are required.

**Author's Contribution:** Development of the main idea and writing the article: Nasibeh Roozbeh, leili Darvish Revision of the study: Nasibeh Roozbeh, leili Darvish and Maryam Azizi.

**Funding/Support:** We received no funding from any organization for this research.

## ACKNOWLEDGMENTS

The authors declare their gratitude towards the kind personnel of the library of Hormozgan University of Medical Sciences for their cooperation in data gathering.

## REFERENCES

- Nicolaidis KH. Nuchal translucency and other first-trimester sonographic markers of chromosomal abnormalities. *Am J Obstet Gynecol.* 2004;191(1):45-67.
- Snijders R, Noble P, Sebire N, Souka A, Nicolaidis K. UK multicentre project on assessment of risk of trisomy 21 by maternal age and fetal nuchal-translucency thickness at 10-14 weeks of gestation. *The Lancet.* 1998;352(9125):343-46
- Grandjean H, Sarramon MF. Sonographic measurement of nuchal skinfold thickness for detection of Down syndrome in the second-trimester fetus: a multicenter prospective study. *J Obstet Gynecol.* 1995;85(1):103-06.
- Watson WJ, Miller RC, Menard MK, Chescheir NC, Katz VL, Hansen WF, et al. Ultrasonographic measurement of fetal nuchal skin to screen for chromosomal abnormalities. *Am J Obstet Gynecol.* 1994;170(2):583.
- Michailidis GD, Economides DL. Nuchal translucency measurement and pregnancy outcome in karyotypically normal fetuses. *Ultrasound Obstet Gynecol.* 2001;17(2):102-05.
- Sepulveda W, Wong AE, Casasbuenas A, Solari A, Alcalde JL. Congenital diaphragmatic hernia in a first-trimester ultrasound aneuploidy screening program. *Prenat Diagn.* 2008;28(6):531-34.
- Sotiriadis A, Papatheodorou S, Makrydimas G. Neurodevelopmental outcome of fetuses with increased nuchal translucency and apparently normal prenatal and/or postnatal assessment: a systematic review. *Ultrasound in Obstetrics & Gynecology.* 2012;39(1):10-09.
- Bilardo C, Timmerman E, Pajkrt E, van Maarle M. Increased nuchal translucency in euploid fetuses what should we be telling the parents? *Prenat Diagn.* 2010; 30(2):93-102.
- Von Elm E, Altman DG, Egger M, Pocock SJ, Gøtzsche PC, Vandenbroucke JP. STROBE Initiative. The Strengthening of Reporting of Observational Studies in Epidemiology (STROBE) statement: guidelines for reporting observational studies. *J Clin Epidemiol.* 2008;61(4):344-49. PMID: 18313558.
- Abdi F, Kazemi F, Ramezani Tehrani F, Roozbeh N. Protocol for systematic review and meta-analysis: hop (Humuluslupulus L.) for menopausal vasomotor symptoms. *BMJ Open.* 2016;6(4):e010734.
- Ghi T, Huggon IC, Zosmer N, Nicolides KH. Incidence of major structural cardiac defects associated with increased nuchal translucency but normal karyotype. *Ultrasound Obstet Gynecol.* 2001;18:610-14.
- Zosmer N, Souter VL, han CSYC, Huggon IC, Nicolaidis KH. Early diagnosis of major cardiac defects in chromosomally normal fetuses with increased nuchal translucency. *Br J Obstet Gynaecol.* 1999;06:829-33.
- Hiippala A, Eronen M, Taipale P, Salonen R, Hiilesmaa V. Fetal nuchal translucency and normal chromosomes: a long-term follow-up study. *Ultrasound Obstet Gynecol.* 2001;18:18-22.
- Vieira LA, Silva SV, de Faria RB, Lippi UG, Lopes RG. Perinatal and pediatric follow up of children with increased nuchal translucency and normal karyotype. *Rev Bras Ginecol Obstet.* 2013;35(6):274-80.
- Matias A, Gomes C, Flack N, Montenegro N, Nicolaidis KH. Screening for chromosomal abnormalities at 10-14 weeks: the role of ductusvenosus blood flow. *Ultrasound Obstet Gynecol.* 1998;12:380-84.
- Jauniaux E, Gavril P, Khun P, Kurdi W, Hyett J, Nicolaidis KH. Fetal heart rate and umbilico-placental Doppler flow velocity waveforms in early pregnancies with a chromosomal abnormality and/or an increased nuchal translucency thickness. *Human Repro.* 1996;11(2):435-39.
- Maymon R, Jauniaux E, Cohen O, Dreazen E, Weinraub Z, Herman A. Pregnancy outcome and infant follow-up of fetuses with abnormally increased first trimester nuchal translucency. *Human Reproduction.* 2000;15(9):2023-27.
- Schwarzler P, Carvalho tJS, Senat MV, Masroor T, Campbell Professor S. Screening for fetal aneuploidies and fetal cardiac abnormalities by nuchal translucency thickness measurement at 10-14 weeks of gestation as part of routine antenatal care in an unselected population. *Br J Obstet Gynaecol.* 1999;106:1029-34.
- Westin M, Saltvedt S, Bergman G, Almström H, Grunewald C, Valentin L. Is measurement of nuchal translucency thickness a useful screening tool for heart defects? A study of 16,383 fetuses. *Ultrasound Obstet Gynecol* 2006;27:632-39.
- Zoppi MA, Ibba RM, Floris M, Monni G. Fetal nuchal translucency screening in 12 495 pregnancies in Sardinia. *Ultrasound Obstet Gynecol.* 2001;18:649-51.
- Nicolides KH, Spencer K, Avgidou K, Faiola S, Falcon O. Multicenter study of first trimester screening for trisomy 21 in 75, 821 pregnancies: results and estimation of the potential impact of individual risk-orientated two-stage first-trimester screening. *Ultrasound Obstet Gynecol.* 2005;25:221-26.
- Taipale P, Hiilesmaa V, Salonen R, Ylöstalo P. Increased Nuchal Translucency as a Marker for Fetal Chromosomal Defects. *N Engl J Med.* 1997;337:1654-58.
- Bijok J, Ziara-Jakutowicz K, Ilnicka A, Pawłowska B, Józwiak A, Dangel J, et al. Increased nuchal translucency in chromosomally normal fetuses and pregnancy outcomes-a retrospective study. *Ginekol Pol.* 2013;84(3):172-79.
- Äyräs O, Tikkanen M, Eronen M, Paavonen J, Stefanovic V. Increased nuchal translucency and pregnancy outcome: a retrospective study of 1063 consecutive singleton pregnancies in a single referral institution. *Prenatal Diagnosis.* 2013;33(9):856-62.
- Dane B, Dane C, Cetin A, Kiray M, Sivri D, Yayla M. Pregnancy outcome in fetuses with increased nuchal translucency. *J Perinatol.* 2008;28:400-04.
- Lithner CU, Kublickas M, Sverker Ek. Pregnancy outcome for fetuses with increased nuchal translucency but normal karyotype. *J Med Screen.* 2016;23(1):01-06.
- Brady AF, Pandya PP, Yuksel B, Greenough A, Patton MA, Nicolaidis KH. Outcome of normal with chromosomally livebirths increased fetal nuchal translucency at 10-14 weeks' gestation. *J Med Genet.* 1998;35:222-24.
- Souka AP, Krampel E, Bakalis S, Heath V, Nicolides KH. Outcome of pregnancy in chromosomally normal fetuses with increased nuchal translucency in the first trimester. *Ultrasound Obstet Gynecol.* 2001;18:9-17.

- [29] Tahmasebpour A, BaradaranRafiee N, Ghaffari S, Jamal A. Increased Nuchal Translucency and Pregnancy Outcome. *IJPH*. 2012;41(11):92-7.
- [30] Mula R, Gonc e A, Benn asar M, Arigita M, Meler E, Nadal A, et al. Increased nuchal translucency and normal karyotype: perinatal and pediatric outcomes at 2 years of age. *Ultrasound Obstet Gynecol*. 2012;39(1):34-41.
- [31] Scholl J, Durfee SM, Russell MA, Heard AJ, Iyer C, Alammari R, et al. First-Trimester Cystic Hygroma: Relationship of Nuchal Translucency Thickness and Outcomes. *Obstet Gynecol*. 2012;120(3):551-59.
- [32] Muru K, Vals M-A, Sitska M, Asser K, Tammur P, Zilina O. Outcome of Children with Marked Changes in Maternal Screening Tests and Normal Karyotype. *Genetics*. 2013; 3:1.
- [33] Czuba B, Borowski D, Cnota W, Sieroszewski P, Grettka K, Pietryga M, et al. Ultrasonographic assessment of fetal nuchal translucency (NT) at 11<sup>th</sup> and 14<sup>th</sup> week of gestation--Polish multicentre study. *Neuro Endocrinol Lett*. 2007;28(2):175-81.

**PARTICULARS OF CONTRIBUTORS:**

1. Faculty, Mother and Child Welfare Research Center, Hormozgan University of Medical Sciences, Bandar, Abbas, Iran.
2. Assistant Professor, Fertility and Infertility Research Center, Hormozgan University of Medical Sciences, Bandar Abbas, Iran.
3. Faculty, Department of Radiology, Faculty of Para-Medicine, Hormozgan University of Medical Sciences, Bandar Abbas, Iran.

**NAME, ADDRESS, E-MAIL ID OF THE CORRESPONDING AUTHOR:**

Leili Darvish,  
Department of Radiology, Faculty of Para-Medicine, Hormozgan University of Medical Sciences, Bandar Abbas, Iran.  
E-mail: leilidarvish@gmail.com

Date of Submission: **Aug 26, 2016**Date of Peer Review: **Sep 09, 2016**Date of Acceptance: **Nov 01, 2016**Date of Publishing: **Mar 01, 2017****FINANCIAL OR OTHER COMPETING INTERESTS:** None.